

# La **DIAGNOSTICA** **EMATOPATOLOGICA** nell'ERA della **MEDICINA** di **PRECISIONE**

## The many faces of inguinal lymph node

*Margherita Vannucchi*

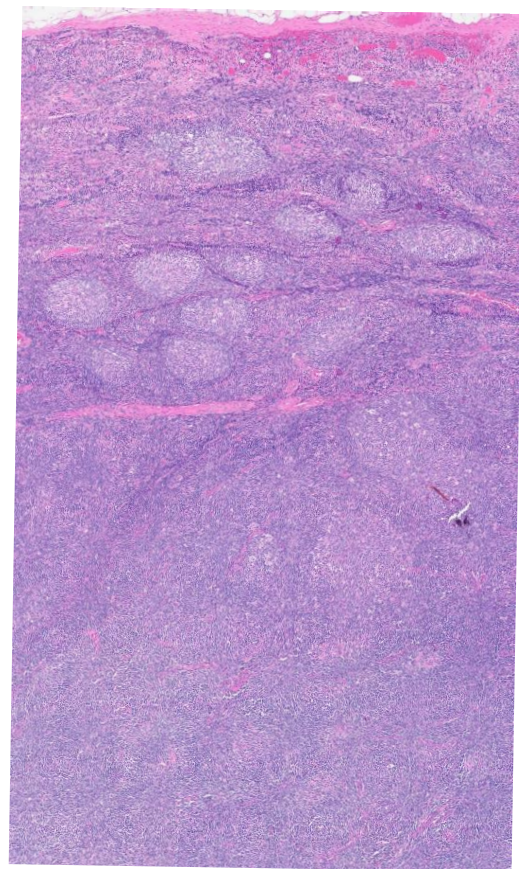
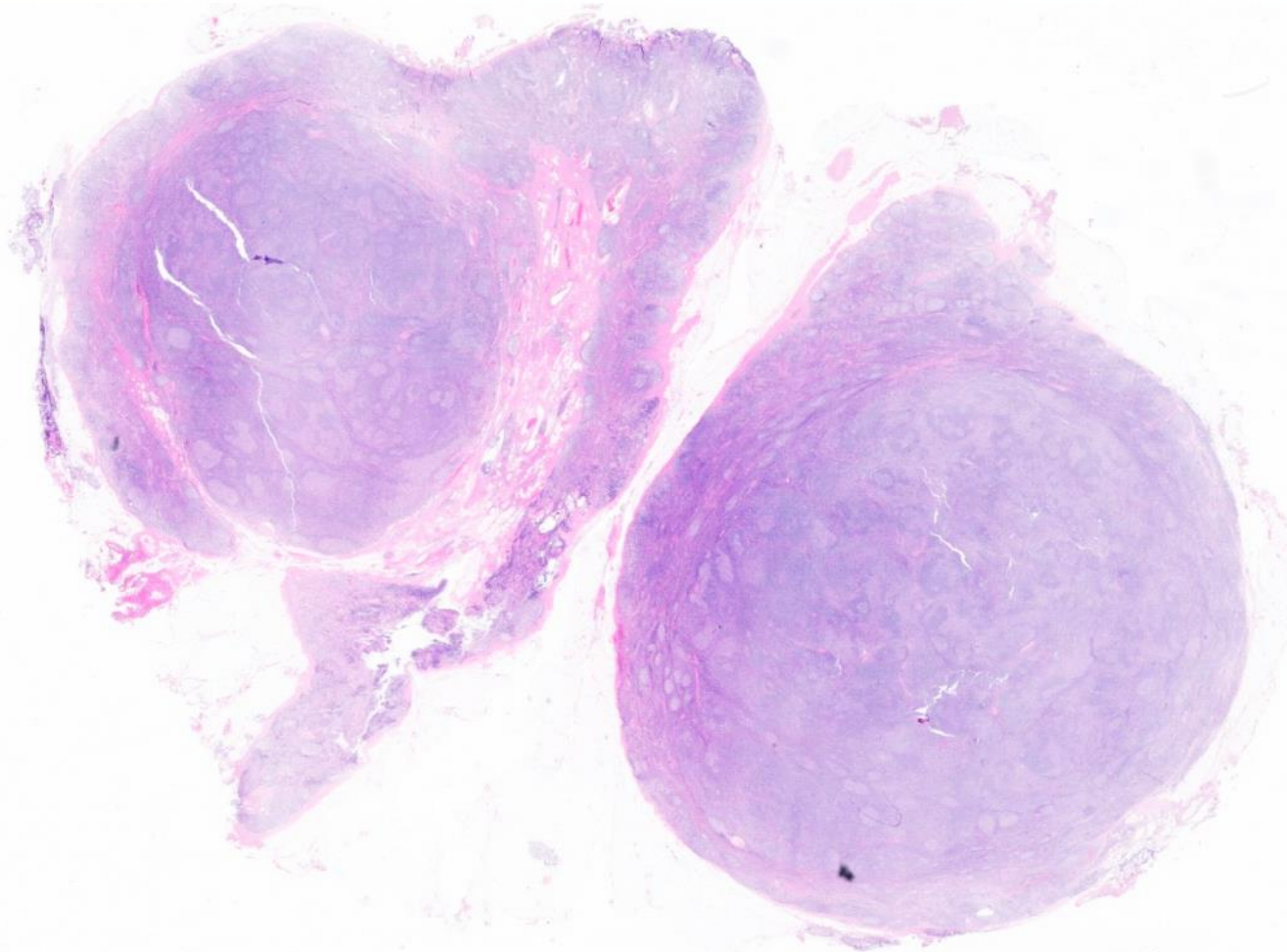


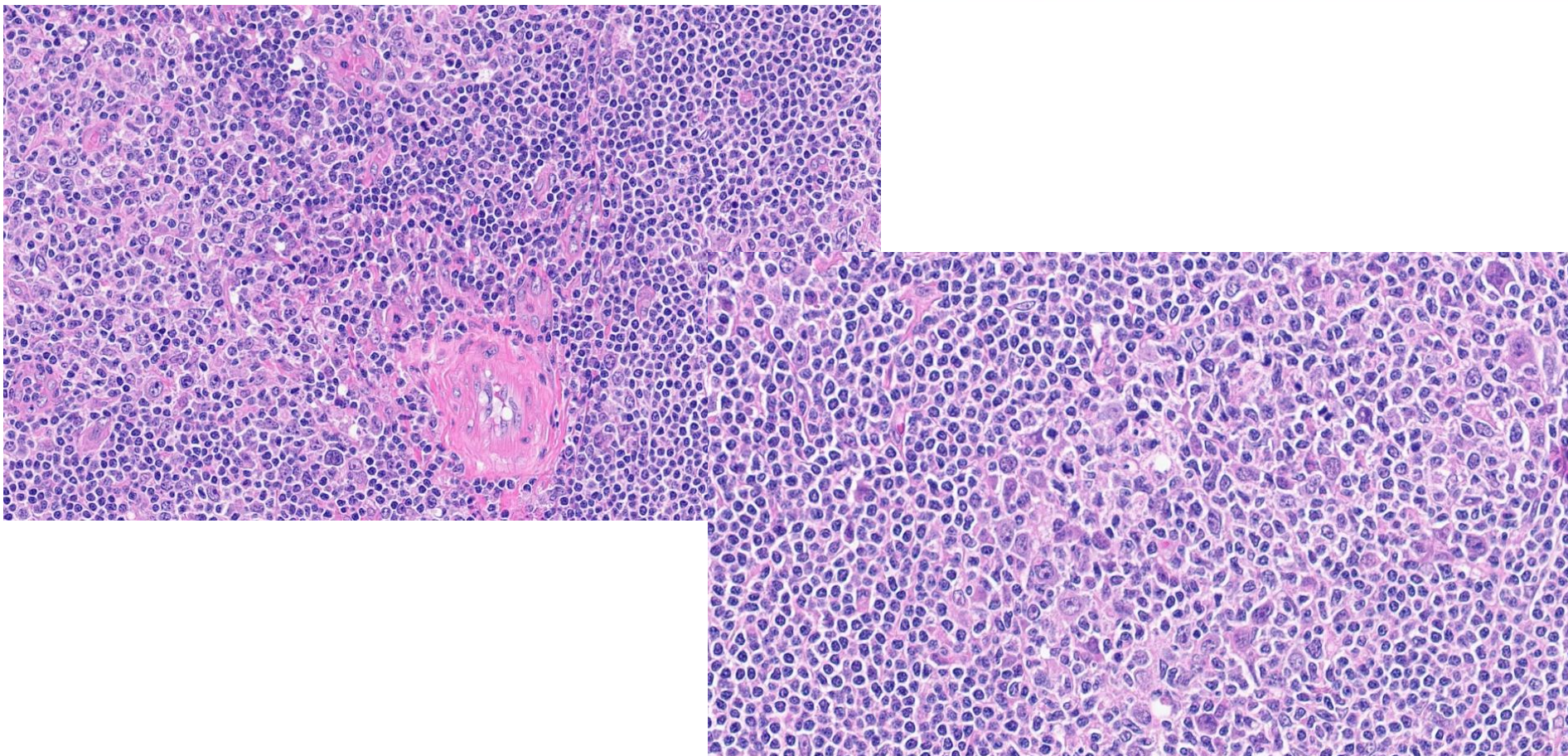
Azienda ospedaliero-universitaria Senese

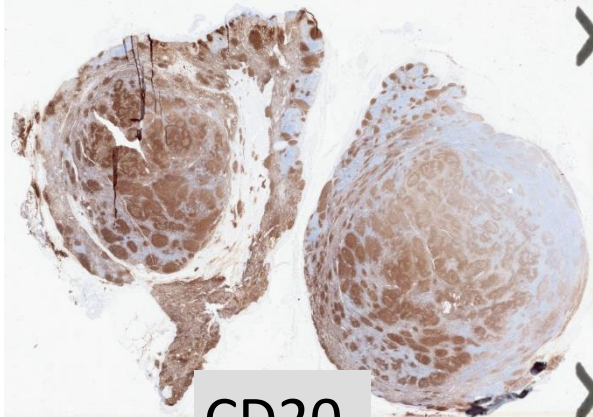




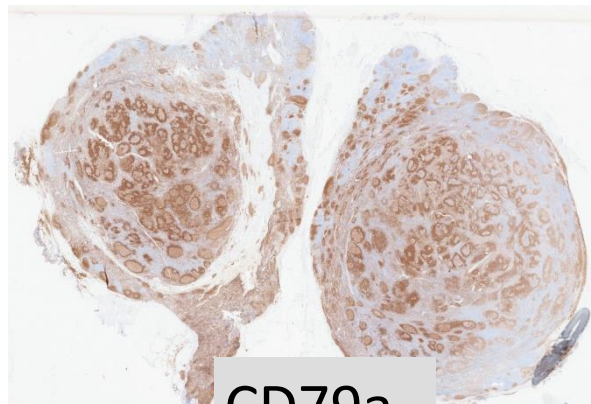
- A 58 years-old woman
- History of breast cancer 9 years ago
- Recently noted an enlargement left inguinal lymph node
- No tender, no systemic symptoms, emogram normal
- Ultrasound examination reveals a homogeneous lymph node measuring 1,8 cm
- The lymph node was excised



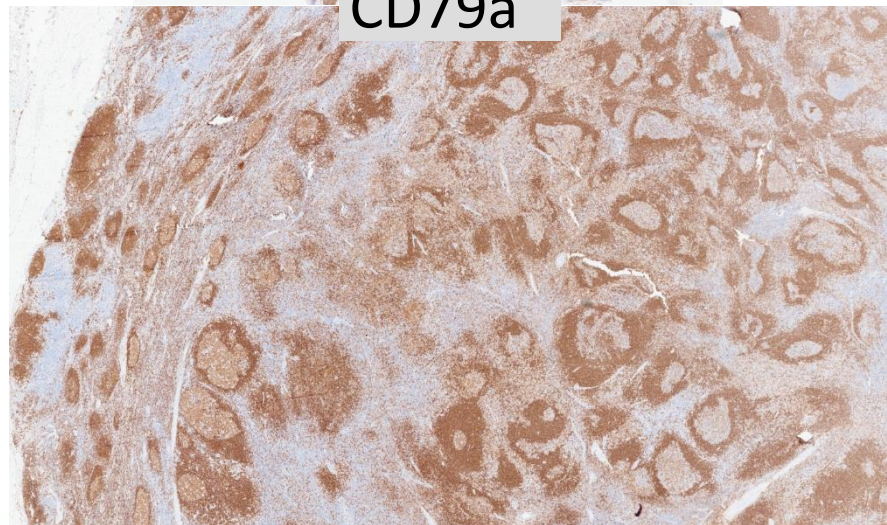
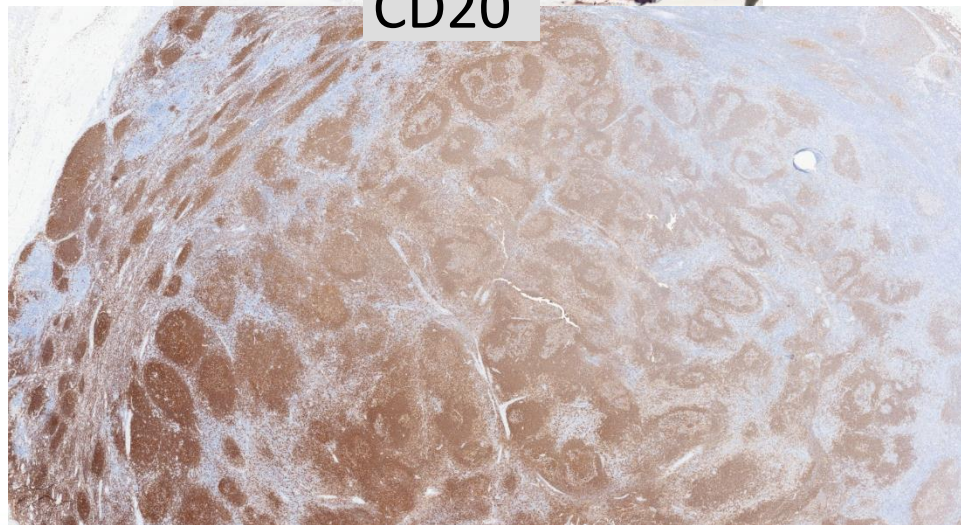


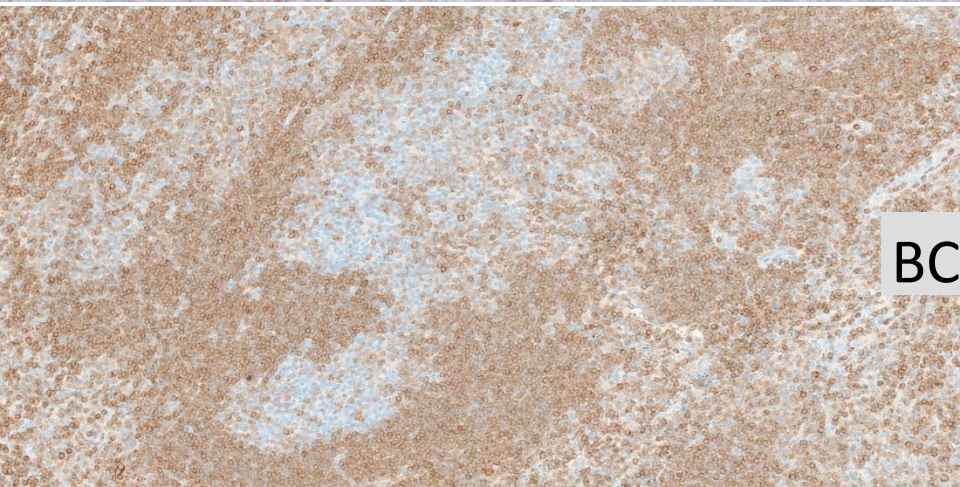
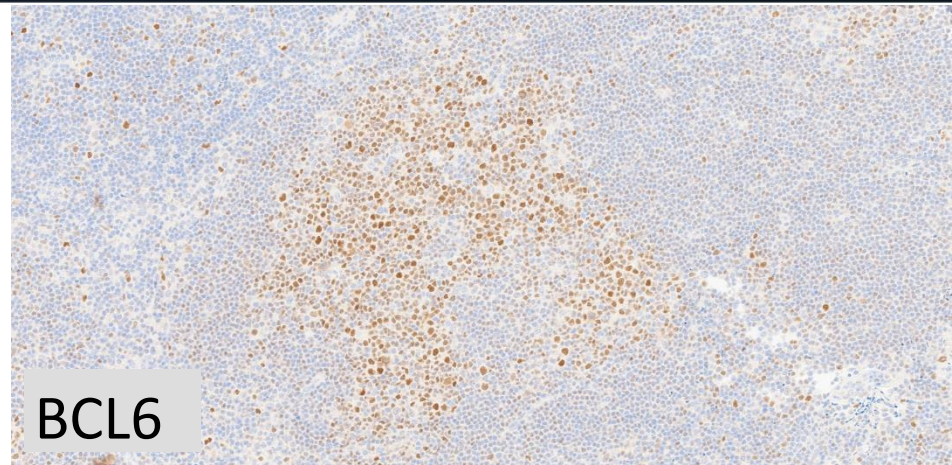
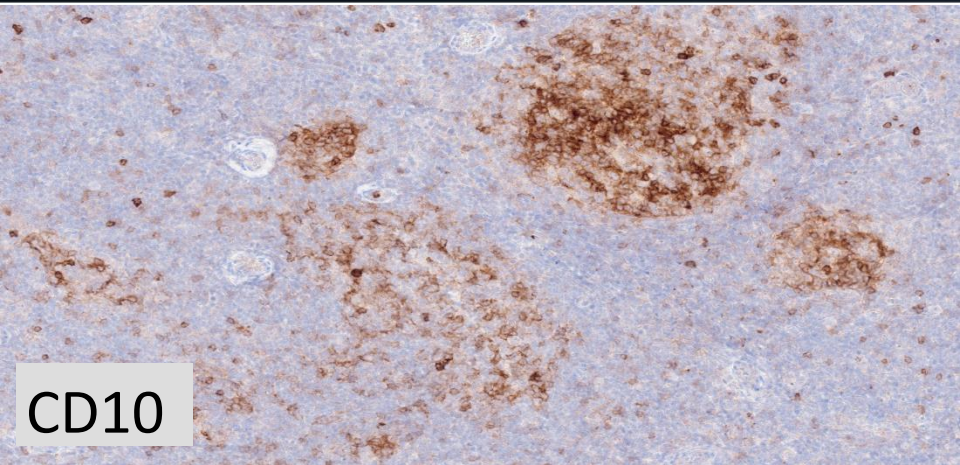


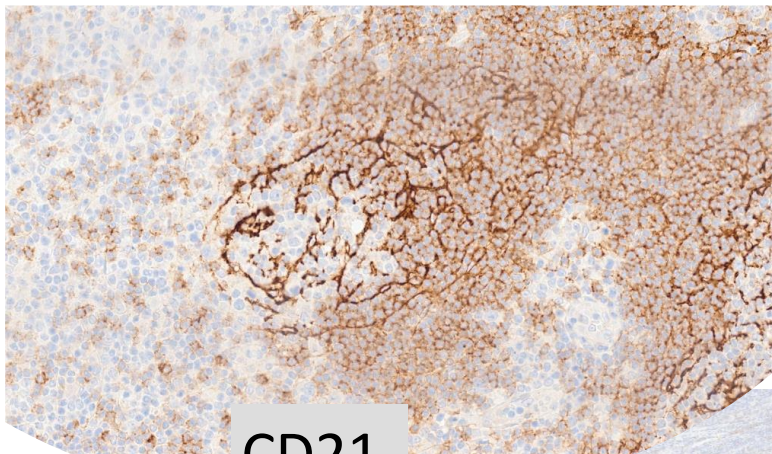
CD20



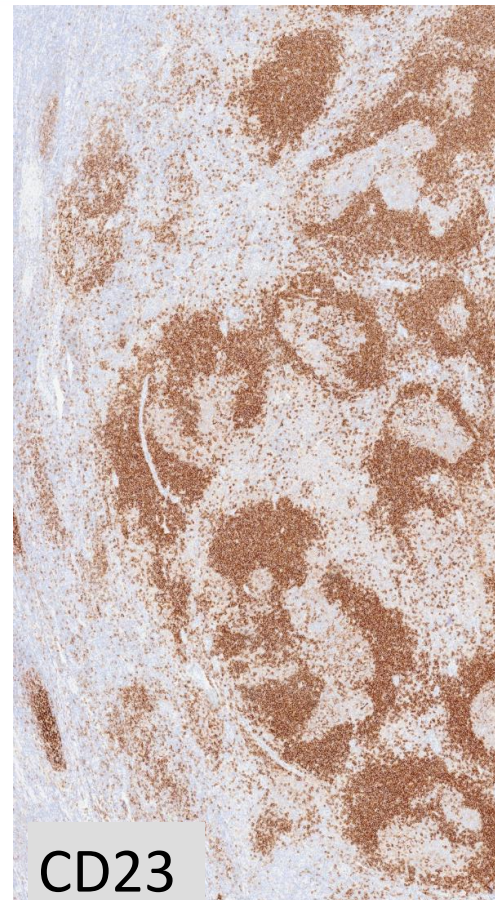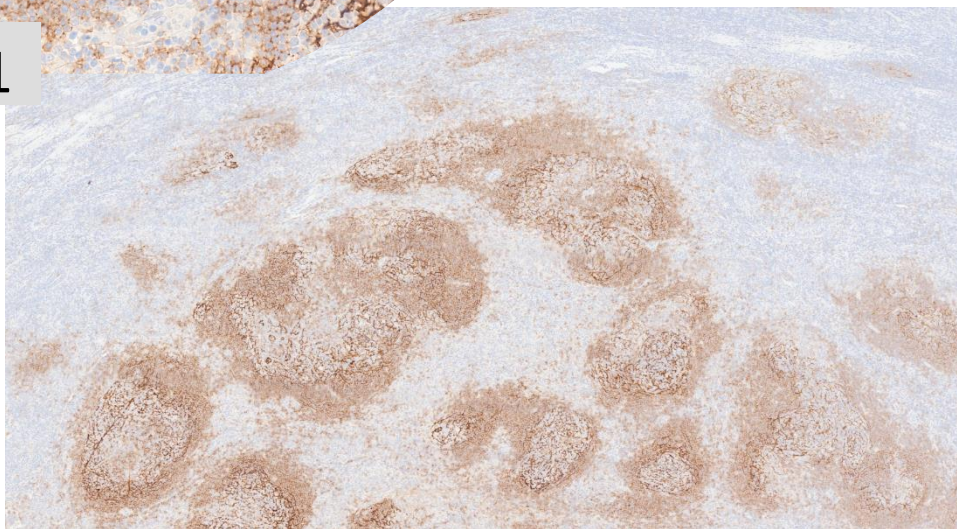
CD79a



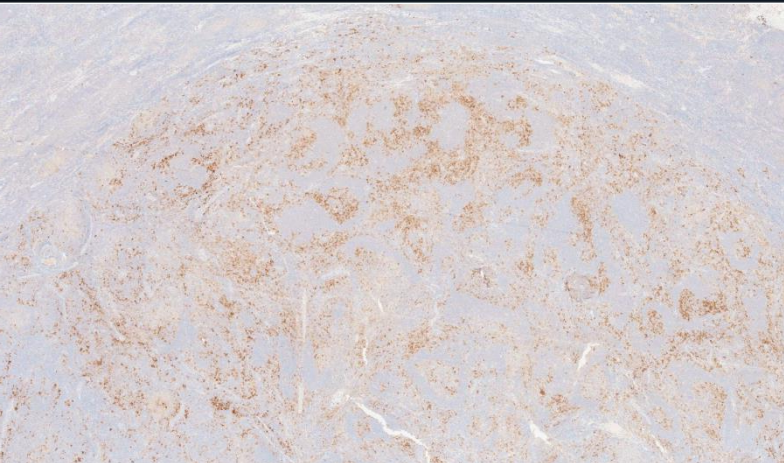




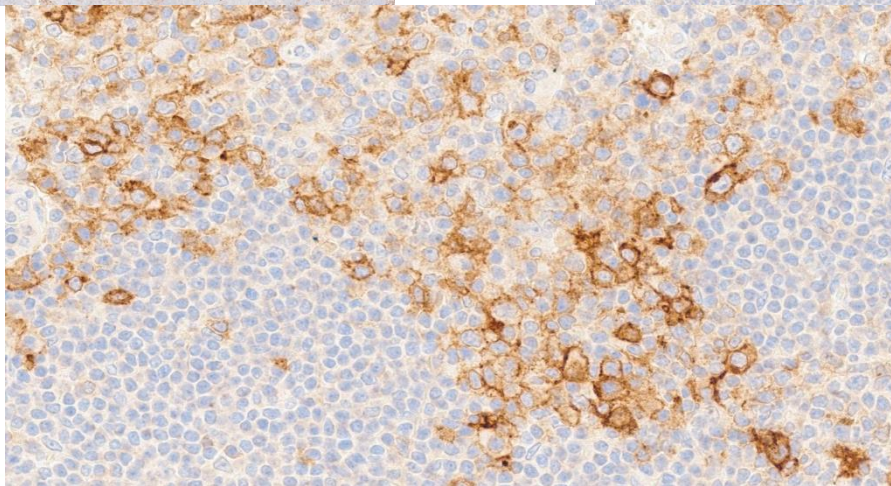
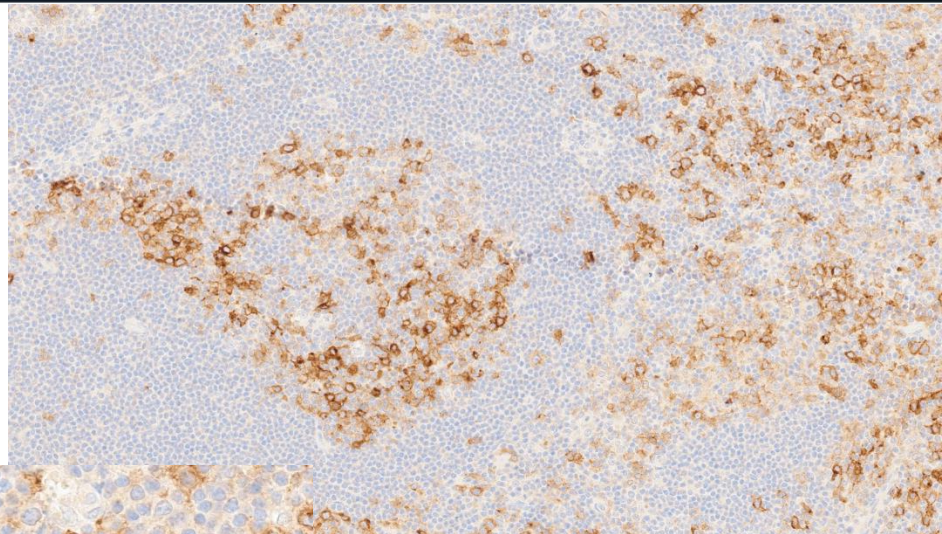
CD21



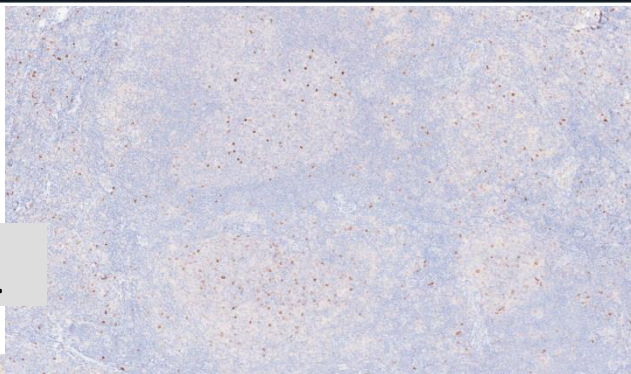
CD23



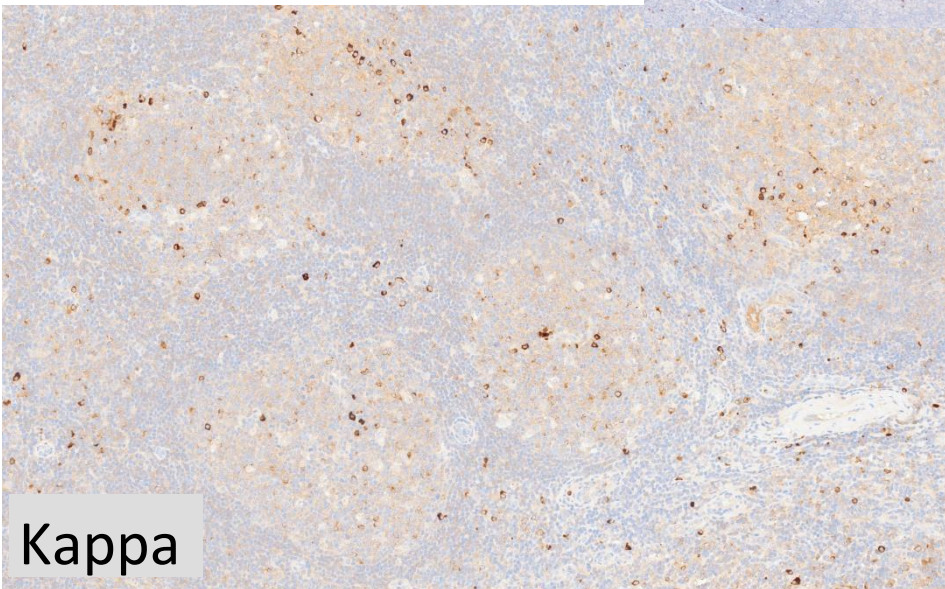
CD30



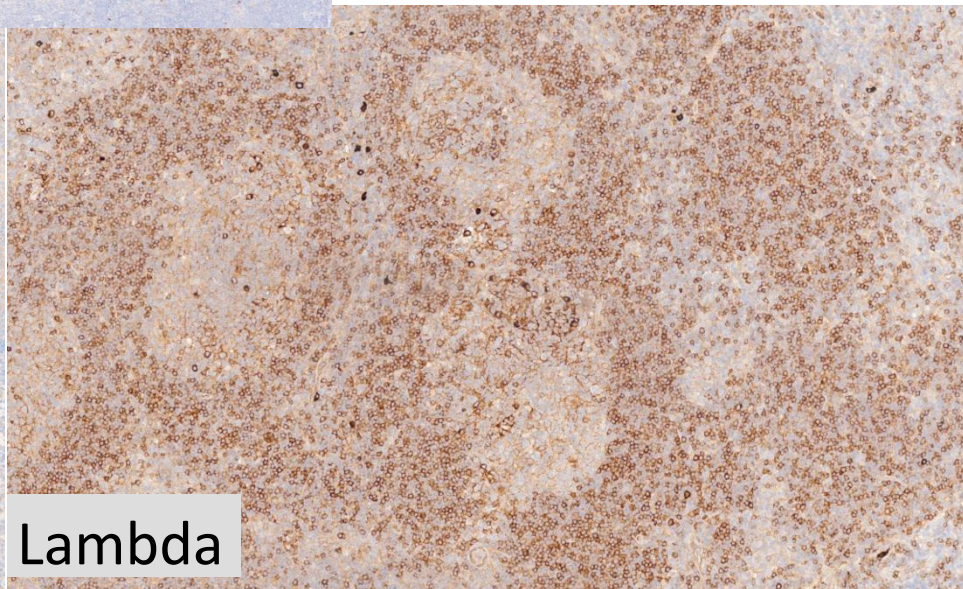
MUM1

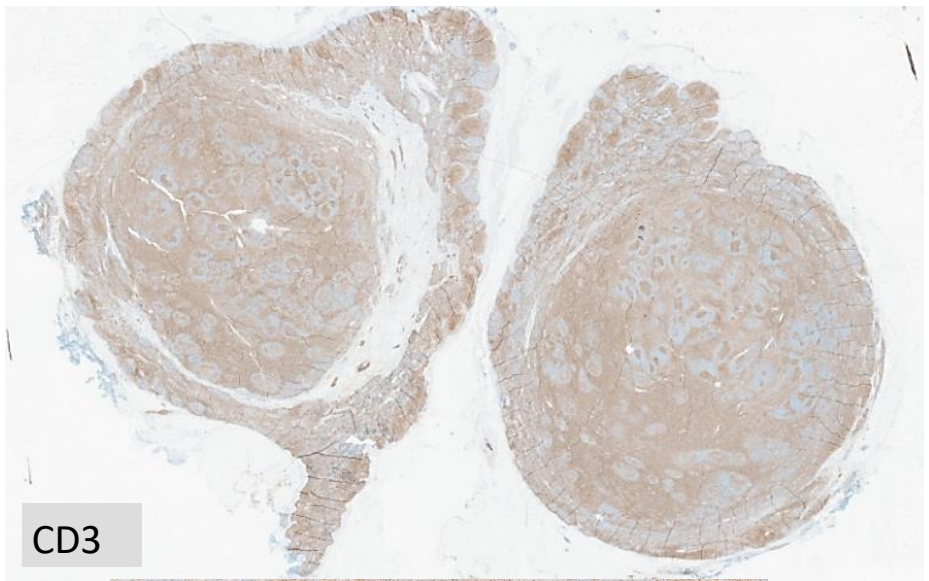


Kappa

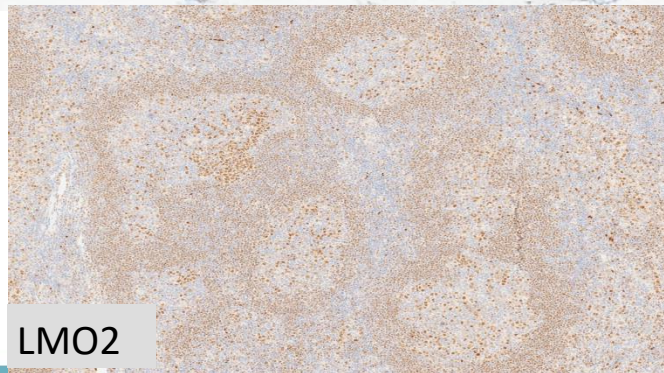


Lambda

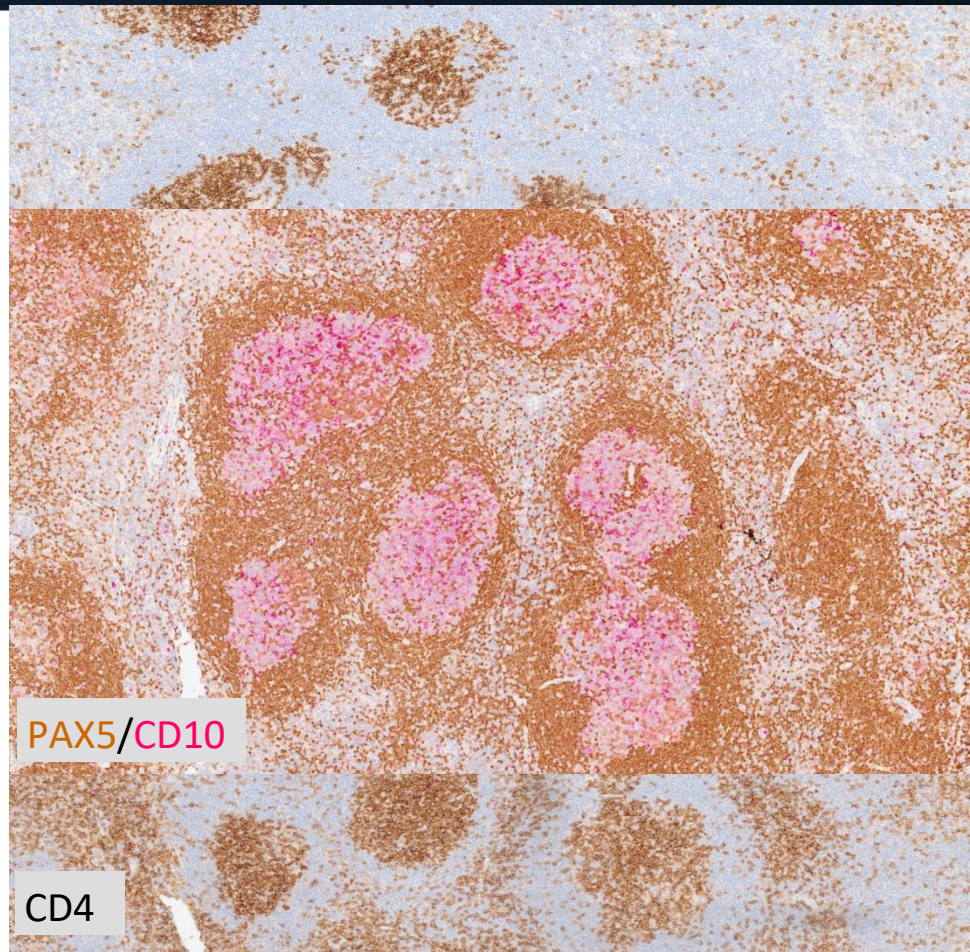




CD3

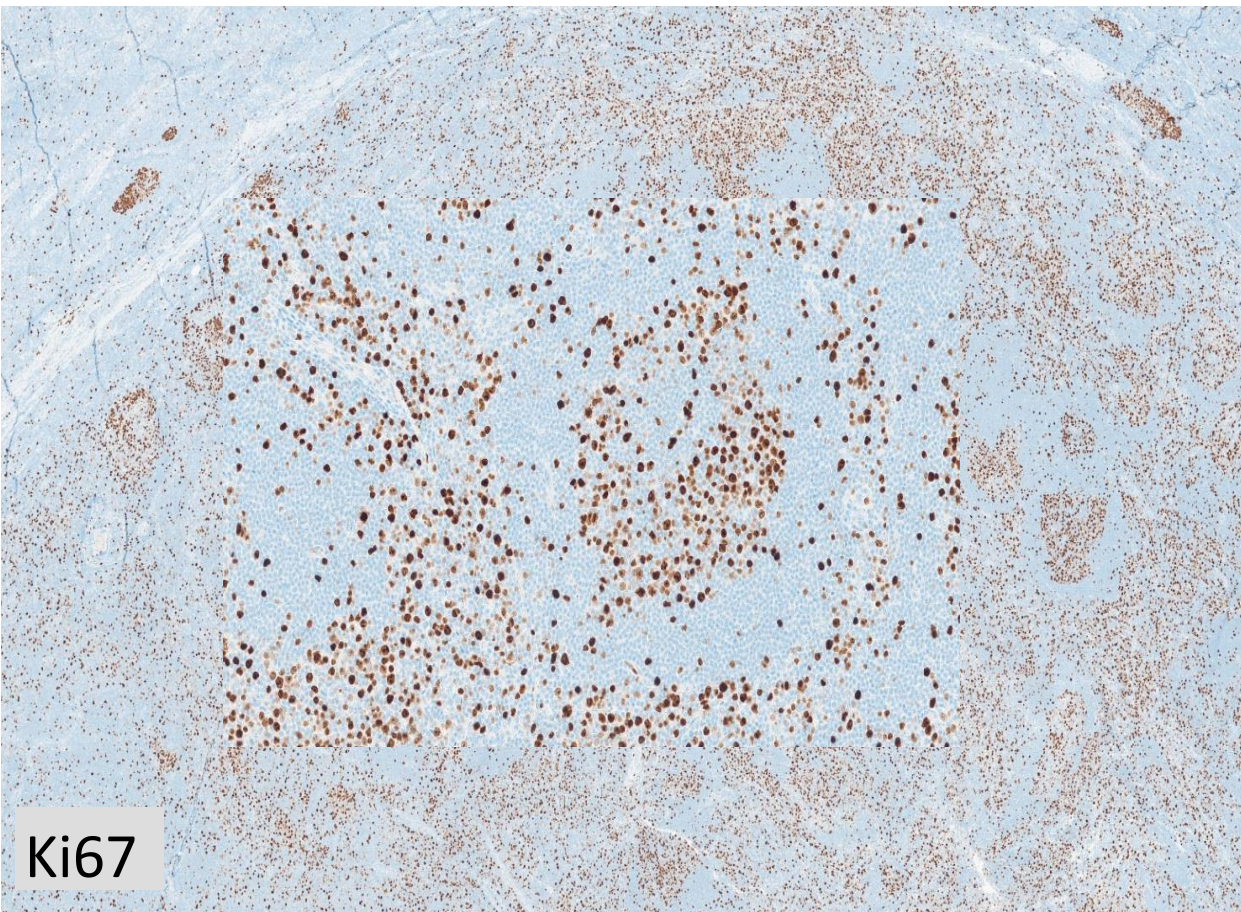


LMO2



PAX5/CD10

CD4



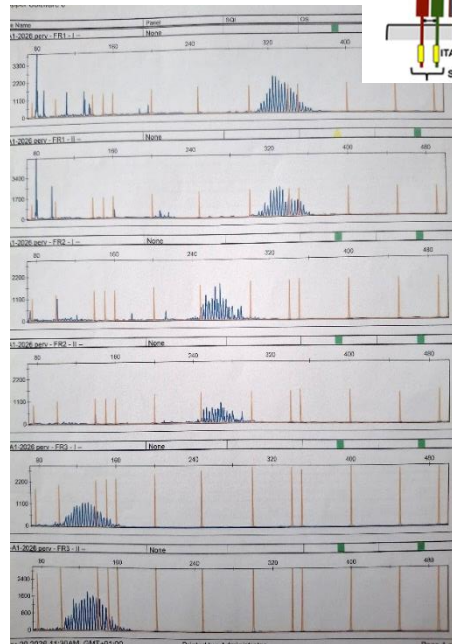
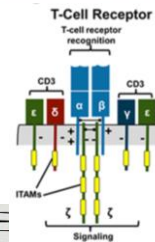
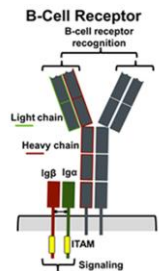
Ki67

EBV-  
MYC<5%

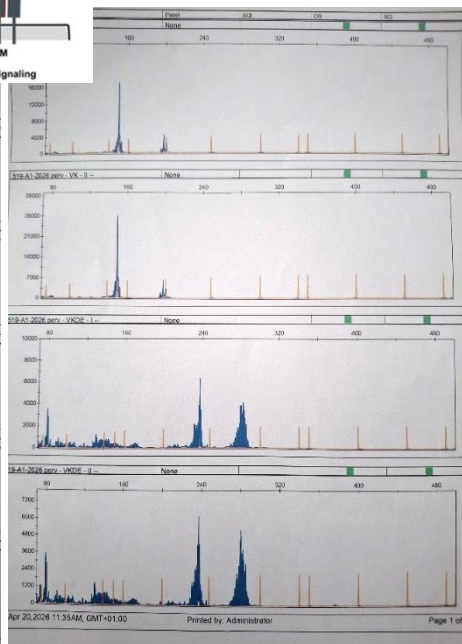
## Diagnostic Hypothesis

- ✓ Atypical Marginal Zone Hyperplasia
- ✓ Marginal Zone Lymphoma
- ✓ Follicular Lymphoma
- ✓ Nodal T follicular helper (TFH) cell lymphoma, follicular type (nTFHL-F)

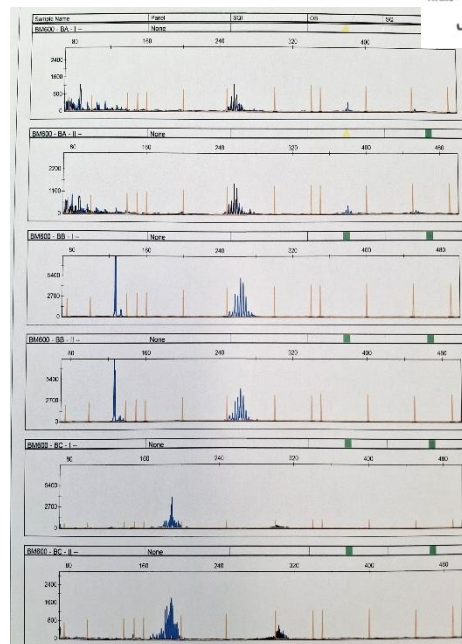
# Clonality studies



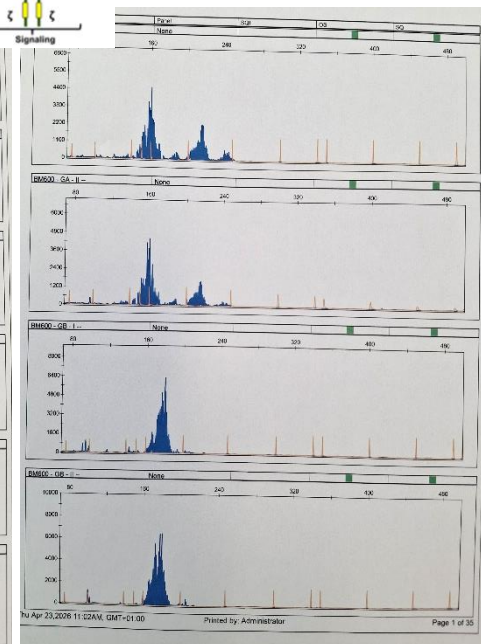
IgH



IgK




TCRβ

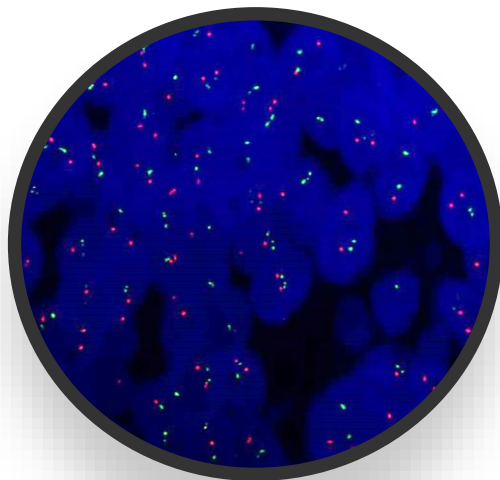


TCRγ


## FISH analysis



BCL2 BA: negative



IgH::BCL2: negative



BCL6 BA: negative

## NGS ANALYSIS

- ✓ Sophia Lymphoma Solution(LYMP\_CLSP\_v3)
- ✓ Filters: Reads>100; VAF  $\geq$ 0.5; gnomAD\_ALL  $\leq$ 0.01

GENE	c.DNA	NM	VAF	Pathogen. Score
<i>CREBBP</i>	c.5039_50941del	NM_004380	6.9	PATO
<i>ARID1A</i>	c.83_92delins	NM_006015	6.7	VUS
<i>EP300</i>	c.1511G>A	NM_001429	49.1	VUS

## Diagnostic Hypothesis a) Atypical MZ Hyperplasia

### Atypical MZ Hyperplasia

Childhood and your adult ++

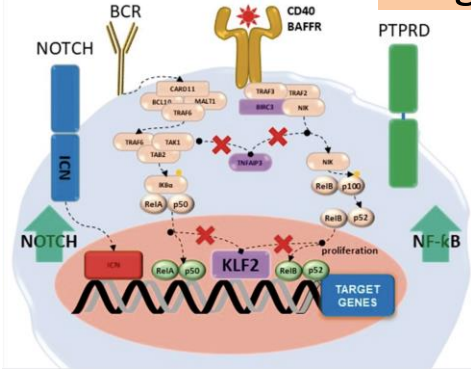
+++ Extranodal

**Non clonal** proliferation

Light chain restriction

Genetic analysis : negative

## Diagnostic Hypothesis b) Marginal Zone Lymphoma



JIM

Genomic landscape in B-cell lymphomas / R. Rosenquist *et al.*

Table 3 Recurrent genetic changes implicated in the pathogenesis of marginal zone lymphoma

Pathway	MALT lymphoma <sup>a</sup>	SMZL	NMZL
NF-κB pathway	t(1;14)(p22;q32)/ <i>BCL10</i> - <i>IGH</i> (0–5%) <sup>b</sup>	<i>CARD11</i> mutation (~7%) <sup>b</sup>	<i>BCL10</i> mutation (11%) <sup>b</sup>
	t(14;18)(q32;q21)/ <i>IGH</i> - <i>MALT1</i> (0–6%) <sup>b</sup>	<i>IKBKB</i> mutation (7%) <sup>b</sup>	<i>CARD11</i> mutation (8%) <sup>b</sup>
	t(11;18)(q21;q21)/ <i>BIRC3</i>	<i>MYD88</i> mutation (5–13%) <sup>b</sup>	<i>MYD88</i> mutation (8%) <sup>b</sup>
	( <i>API2</i> )- <i>MALT1</i> (0–38%) <sup>b</sup>	<i>TNFAIP3</i> mutation (7–13%)	<i>REL</i> mutation (11%)
	<i>MYD88</i> mutation (5–19%) <sup>b</sup>	<i>BIRC3</i> mutation (6%)	<i>TNFAIP3</i> mutation (14%)
	<i>TNFAIP3</i> mutation (~28%)	<i>TRAF3</i> mutation (5%)	<i>BIRC3</i> mutation (5%)
		<i>NOTCH2</i> mutation (7–25%) <sup>b</sup>	<i>NOTCH2</i> mutation (20%) <sup>b</sup>
		<i>NOTCH1</i> mutation (5%) <sup>b</sup>	<i>NOTCH1</i> mutation (6%) <sup>b</sup>
		<i>SPEN</i> mutation (5%)	<i>SPEN</i> mutation (14%)
		<i>DTX1</i> mutation (2%)	<i>RBPJL</i> mutation (5%)
			<i>DTX1</i> mutation (3%)
		<i>KLF2</i> mutation (20–40%)	<i>KLF2</i> mutation (17%)
		<i>TP53</i> mutation (~12%)	<i>PTPRD</i> mutation (20%)

Table 2. Recurrent molecular lesions in SMZL (continued)

Lesion	Prevalence	Genomic location, target genes, functions, and associations	References
<i>MYD88</i>	5–15%	A small proportion of <i>MYD88</i> mutations in SMZL are L265P (6%). Role in MZ B-cell differentiation, and its absence leads to a deficiency in their availability. Promotion of B-cell proliferation and survival by activation of NF-κB.	[72–79]
<i>KMT2D</i>	11–15%	Frequent in all lymphoid tumours, mutants have delayed GC formation.	[80, 81]
<i>CREBBP</i>	Approximately 5%	Mutations were found to be fully clonal and likely early initiating events, like that in FL. Frequent in DLBCL and FL. Regulates enhancer networks with a crucial role in GC/post-GC cell fate decisions.	[53, 82, 83]

BCR: B-cell receptor; SMZL: splenic marginal zone lymphoma; MZLs: marginal zone lymphomas; MDR: minimally deleted region; CLL: chronic lymphocytic leukaemia; MZ: marginal zone; NF-κB: nuclear factor kappaB; GC: gastric cancer; FL: follicular lymphoma

Description of nodal marginal zone lymphoma cases with increased T follicular helper cells

Case number	Age	Sex	Disease localization	Clonality	NGS
LYWS-1031	60	M	Multiple	B+, T-	<i>NOTCH2</i> , <i>CREBBP</i> , and <i>KLF2</i> mutations
LYWS-1037	53	F	Axillary	B+, T-	Negative for <i>TET2</i> , <i>RHOA</i> , <i>DNMT3A</i> , and <i>IDH2</i> mutations
LYWS-1039	77	F	Multiple	B+, T-	<i>NOTCH2</i> and <i>KLF2</i> mutations
LYWS-1051	60	F	Axillary, inguinal, kidney	B+, T-	<i>CD70</i> , <i>IRF4</i> , <i>TMSB4X</i> , and <i>BTG2</i> mutations
LYWS-1082	78	F	Inguinal, pelvic	B+, T-	n.a.
LYWS-1168	91	F	Mediastinal and hilar	B+, T-	<i>NOTCH2</i> , <i>CCND3</i> , <i>IRF8</i> , and <i>NOTCH1</i> mutations
LYWS-1347	55	F	Multiple	B+, T-	<i>SPEN</i> (2x) and <i>TNFAIP3</i> mutations
LYWS-1433	57	F	Inguinal	B+, T-	Neg

### The many faces of nodal and splenic marginal zone lymphomas. A report of the 2022 EA4HP/SH lymphoma workshop

[Alberto Zamò](#)<sup>1,8</sup>, [Michiel van den Brand](#)<sup>2,3,8</sup>, [Fina Climent](#)<sup>4</sup>, [Laurence de Leval](#)<sup>5</sup>, [Stefan Dirnhofer](#)<sup>6</sup>, [Lorenzo Leoncini](#)<sup>7</sup>, [Siok-Bian Ng](#)<sup>8,9</sup>, [Sarah L Ondrejka](#)<sup>10</sup>, [Leticia Quintanilla-Martinez](#)<sup>11</sup>, [Lorinda Soma](#)<sup>12</sup>, [Andrew Wotherspoon](#)<sup>13</sup>

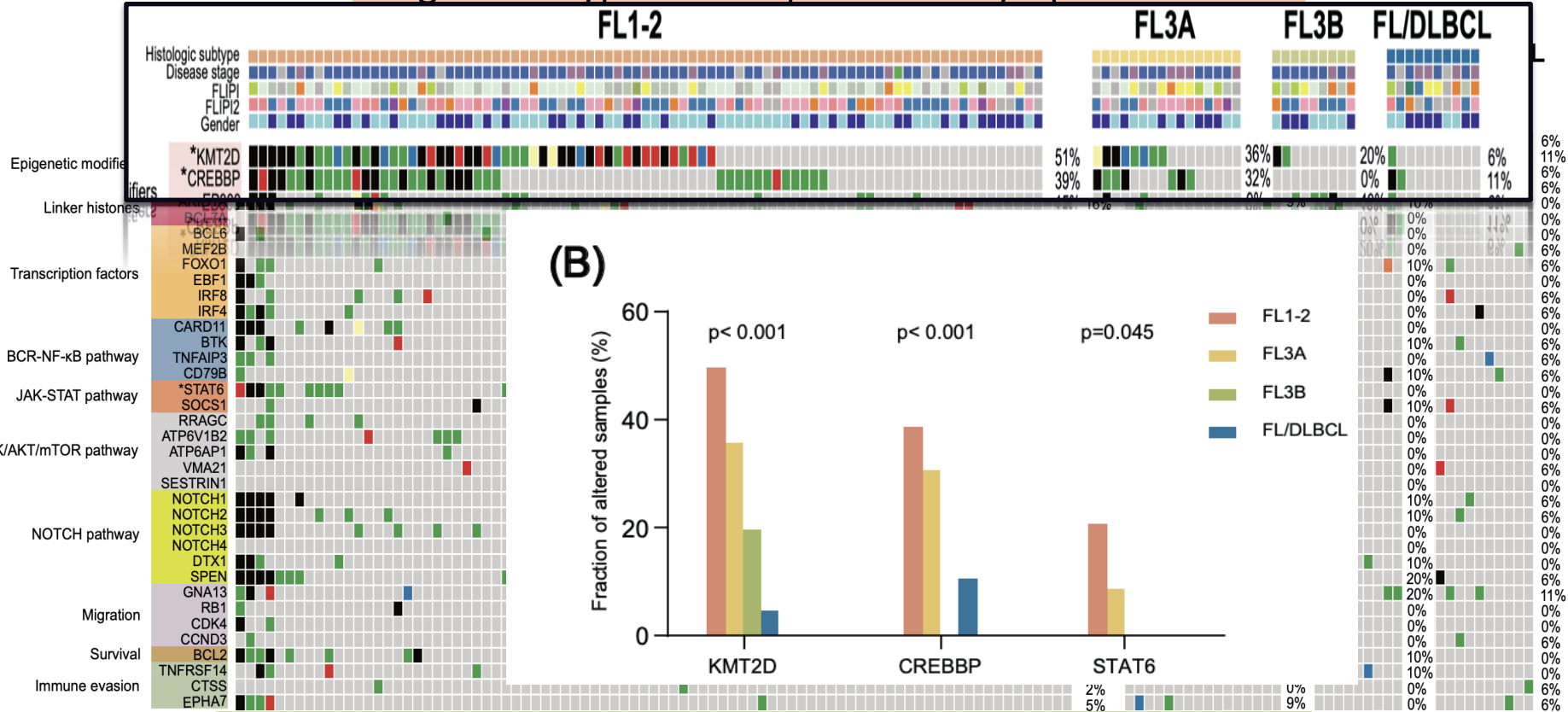
## Diagnostic Hypothesis c) Follicular Lymphoma

Most frequent gene alterations in *BCL2*-rearranged follicular lymphoma at diagnosis

Gene	Frequency of alterations*	Predominant type(s) of alteration
<i>KMT2D (MLL2)</i>	50–70%	Mutation
<i>CREBBP</i>	50–70%	Mutation (~60%), deletion
<i>EPHA7</i>	70%	Deletion, methylation
<i>TNFRSF14</i>	45–65%	Deletion, mutation (~30%)
<i>BCL2</i>	~50%	Mutation
<i>SESNI</i>	30–40%	Deletion
<i>CDK4</i>	~30%	Gain
<i>EZH2</i>	20–40%	Mutation (~20%), gain
<i>H1-2 to H1-5 (HIST1H1B–E)</i>	15–30%	Mutation
<i>CTSS</i>	15–20%	Mutation (~5%), amplification
<i>BCL6</i>	~15%	Translocation, mutation (~5%)

*Alaggio R, The 5th edition of the World Health Organization Classification of Haematolymphoid Tumours: Lymphoid Neoplasms*

## Diagnostic Hypothesis c) Follicular Lymphoma



Sun C, Molecular landscape of distinct follicular lymphoma histologic grades: insights from genomic and transcriptome analyses. *Leukemia*. 2025



Proposed diagnosis based on NGS results :

Follicular lymphoma with features of  
marginal zone lymphoma

- ✓ No symptoms
- ✓ Only one lymph node involved
- ✓ TC and PET negative



Watch and wait

Proposed diagnosis based on morphology :

MZL lymphoma rich in CD30+ cells and T fh lymphocytes



CREBBP mutations reported also in DLBCL

**Could be interpreted these features as an early phase of MZL transformation in a DLBCL, albeit without typical MZL mutations?**

# Conclusions

- ✓ Overlapping features between **Marginal**, **Follicular** and **nodal Tfh** lymphoma
- ✓ NGS can help (unfortunately not always !) in the differential diagnosis